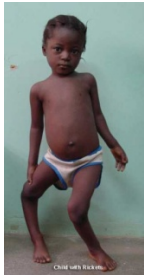

## 4 YEAR OLD GIRL WITH BONY DEFORMITIES

### This case study aims to

- Help understand the clinical presentation of rickets
- State the risk factors for rickets
- Discuss the management of rickets

Rani, a four year old girl is brought to the primary health centre for not being to walk properly.



On examination, there are skeletal deformities of both upper and lower limbs with marked bowing

General examination shows pallor, otherwise there are no other signs. The abdomen is distended, otherwise systemic examination is normal.

### 1. Based on the above history and examination, the diagnosis is

- a) Vitamin A deficiency
  - b) Scurvy
  - c) **Rickets**
  - d) None of the above
- Rickets is a disease of growing bone that is unique to children

### 2. The causes of rickets are

- a) Lack of sunlight
- b) Eating foods not containing Vitamin D
- c) **Both of the above**
- d) Neither of the above

Causes of rickets are

- *Lack of vitamin D*  
vitamin D is got from two sources:
  - *Sunlight.* Vitamin D is produced in the skin when it's exposed to sunlight. Lack of exposure to sunlight means no production of Vitamin D in the skin.
  - *Food.* Fish oils, fatty fish and egg yolks contain vitamin D. Vitamin D also has been added to some foods, such as milk, cereal and some fruit juices. Children who don't eat enough of these fortified foods can develop a vitamin D deficiency.
- **Problems with absorption**
  - Celiac disease

- Inflammatory bowel disease
- Cystic fibrosis
- Renal diseases (e.g. renal tubular acidosis)

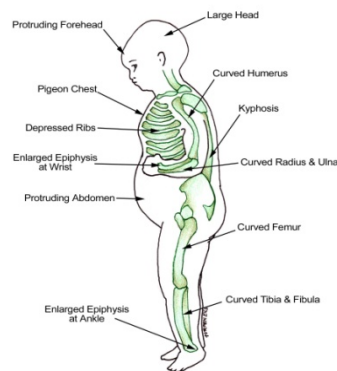
### 3. Risk factors for developing rickets are

- Dark skin
- Exclusive Breast feeding without Vitamin D supplementation
- Inadequate exposure to sunlight
- All of the above**

Risk factors for developing rickets -

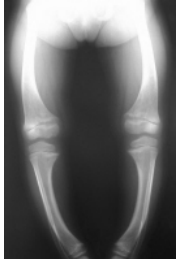- Children ages 6 months to 24 months are at the highest risk of rickets because of rapid bony growth during this period
- Other risk factors include
  - Dark skin
  - Inadequate exposure to sunlight
  - Decreased intake of foods containing vitamin D, calcium or phosphorus
  - Breastfeeding without a vitamin D supplement

### 4. What are the clinical features of rickets?



- Craniotabes manifests early in infants with vitamin D deficiency
- Frontal bossing and delayed closure of the anterior fontanelle
- Enlargement of the metaphyses producing knobby deformity
- Weight bearing produces deformities such as bowlegs and knock-knee
- In the chest, knobby deformities results in the rachitic rosary along the costochondral junctions.
- The weakened ribs pulled by muscles also produce flaring over the diaphragm, which is known as Harrison sulcus
- The sternum may be pulled into a pigeon-breast deformity.
- In more severe instances in children older than 2 years, vertebral softening leads to kyphoscoliosis.
- Because the softened long bones may bend, they may fracture one side of the cortex (i.e., greenstick fracture)
- Generalized muscular hypotonia

### 5. What are the X-ray findings in rickets?



The X-ray findings in rickets include

- bowing of the legs
- The metaphyses exhibit widening and cupping.
- Along the shaft, the uncalcified osteoid causes the periosteum to appear separated from the diaphysis.
- Generalized osteomalacia occurs (observed as osteopenia), with visible coarsening of trabeculae

#### 6. How would you treat this child?

- Vitamin D may be gradually administered
  - over several months - 5000-10,000 U given daily for 2-3 months until healing is well established and the alkaline phosphatase concentration is approaching the reference range
  - or in a single-day dose of 600,000 U of vitamin D
- Orthopaedic correction of If severe deformities may be required after healing. Most of the deformities correct with growth.

#### 7. Can rickets be prevented?

Adequate ultraviolet light 20 min/d of ultraviolet light to the face of a light-skinned baby / significantly longer periods of exposure for children with increased skin pigmentation, 400 IU orally (PO) daily of a vitamin D preparation and an adequate dietary supply of calcium and phosphorus prevent rickets.

Infants weighing less than 1500 g need special supplementation (i.e., vitamin D, calcium, phosphorus) if breast milk is their primary dietary source. Recommending a vitamin D supplement from the first week of life for susceptible infants who are breastfed is safe and effective and, therefore, should be practised

#### References

1. Larry A. Greenbaum Rickets, Chapter 48, Kliegman: Nelson Textbook of Pediatrics, 18th ed, 2007
2. Prevention of rickets and vitamin D deficiency in infants, children, and adolescents. *Pediatrics*. Nov 2008;122(5):1142-52